

## Demodex Outbreak Causing Palpebra Skin Lesions

Stergios Karapsias\*, Andreas Patelis and Agathi Sgourou

Clinical Microbiology Laboratory, 251 General Air Force Hospital, Athens, Greece

\*Corresponding author: Stergios Karapsias, Clinical Microbiology Laboratory, 251 General Air Force Hospital, Athens, Greece, Tel: 0306983521853; E-mail: [kast594594@yahoo.gr](mailto:kast594594@yahoo.gr)

Received date: February 28, 2017; Accepted date: March 07, 2017; Published date: March 14, 2017

Copyright: © 2017 Karapsias S, et al. This is an open-access article distributed under the terms of the Creative Commons Attribution License, which permits unrestricted use, distribution, and reproduction in any medium, provided the original author and source are credited.

### Abstract

Demodex spp may cause blepharitis and palpebra skin lesions. Since eyelash demodicosis seems to be quite spreadable in the community, every patient with chronic non-diagnosed blepharitis should be examined for Demodex spp. Tea tree oil treatment may be an efficient and safe therapeutical choice against ocular demodicosis.

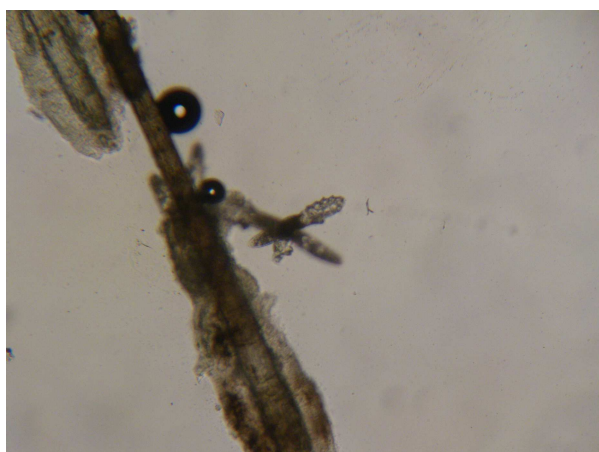**Keywords:** Demodex; Ocular demodicosis; Blepharitis; Tea tree oil

### Introduction

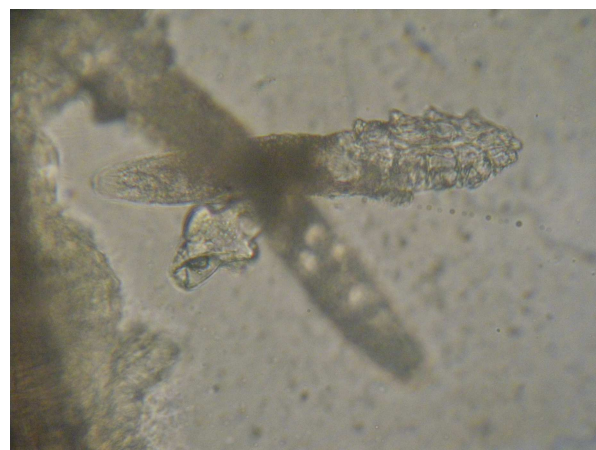Demodicidae species and especially Demodex spp parasite into animal mammal follicles and may cause skin lesions to human subjects, too. The aim of the study is to report an outbreak of ocular skin (palpebra) infections due to Demodex, among community population.

### Materials and Methods

The study comprised all eyelash specimens collected at the ophthalmological community wards and examined for *Demodex* spp. (Figures 1 and 2) at the Clinical Microbiology Laboratory of the Hellenic General Air Force Hospital in Athens, from June 1st 2016 to December 31st 2016.

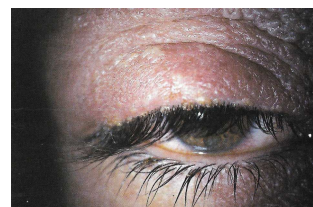

**Figure 1:** *Demodex* spp. onto eyelash (lenses 10 × 10, magnification x100).



**Figure 2:** *Demodex* spp. onto eyelash (lenses 10 × 40, magnification x400).

All patients had symptoms of blepharitis, no response to treatment with antimicrobial collyria, negative ocular microbiological cultures and negative Chlamydia examinations. Palpebra skin lesions included mild edema, itch, mild or no erythema combined with intense smegma secretion from eyelash follicles (Figure 3).



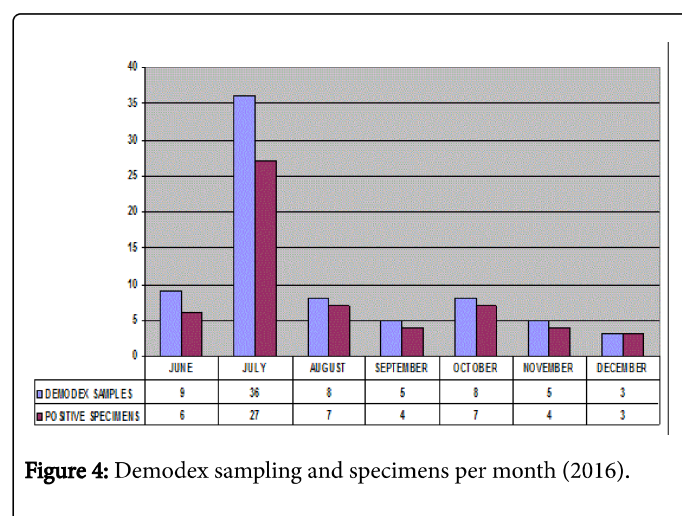
**Figure 3:** Palpebra skin lesions due to *Demodex* spp.

Every eyelash sample included at least four eyelashes, one from each upper and lower palpebra of the patient, and was examined by optical

microscope (lenses 10 × 10 and 10 × 40, total magnification x100 and x400 respectively).

## Results

Within a seven-month period, 74 eyelash examinations for Demodex were registered, 28 from male (37.84%) and 46 from female subjects (62.16%). 58 samples were positive for Demodex spp (78.38% overall), 22 from male (78.57% overall men) and 36 from female subjects (78.26% overall women). Positive samples were statistically related neither to the month of sample collection nor to patients' gender (chi-square [x2] criterion). Additionally, most of the patients declared they weren't owners of mammal pets. Distribution of all demodicosis cases throughout time is shown in Figure 4.



**Figure 4:** Demodex sampling and specimens per month (2016).

Demodex treatment has not a standardised methodology yet. Oral administration of ivermectin could be an evidence based treatment for all patients [1] but ivermectin is not practically available in Greece. Oil of Melacula tree (tea tree oil, TTO) was our final therapeutic decision due to encouraging bibliographic data [2-5] and its clinical safety [2]. In the beginning, all patients had been treated for four to six weeks by daily use of various commercial cosmetic shampoos containing TTO up to 5%. Daily TTO shampooing, for at least 5 min, included massaging and scrubbing patients' hair, head, neck and of course both eyelids and all eyelashes. Patients were advised to apply warm water or chamomile compresses onto their eyelids for 10 min just before their TTO shampooing treatment, in order to improve Demodex discard during TTO eyelid scrubbing.

Nearly half of the patients were fully relieved from Demodex after 1-1.5 month of shampooing, but the other half of them were not. These patients continued TTO shampooing and additionally underwent daily treatment with TTO 5-10%, diluted in mineral oil [2-5], depending on the patients' endurance to TTO ocular irritation. Application of TTO 5-10% was done by a cotton tip onto eyelid and eyelashes. Five to ten minutes after TTO application, eyelids and eyelashes were scrubbed for approximately 5 minutes, according to bibliography [2-5]. Patients were advised to perform TTO eye scrubbing twice a day. After four to six weeks of the combinational treatment using TTO shampoos and 5-10% TTO eyelash scrubbing, most of the patients were free of discomfort and Demodex. Patients, who still suffered from ocular discomfort and were not Demodex-free, were the ones who had poor compliance with the treatment or were forced to disrupt the treatment due to intense TTO ocular irritation.

## Discussion

Observation of arachnids *Demodex folliculorum* and *brevis* in the pilosebaceous components of the eyelid of humans has been reported since 1840. In humans, demodex is also found on facial skin especially the forehead, cheeks, sides of the nose, eyelashes and external ear canals. It sometimes causes a condition called demodicosis. Demodicosis results in non-specific symptoms and signs on facial skin, mostly follicular scales, redness, sensitive skin and mild itch [6]. Demodectic frost of the ear, otitis externa, perioral dermatitis and rosacea have also been described in humans [7,8].

Treatment of palpebra demodicosis usually lasts a few months [1-9]. The use of various substances such as yellow mercurial ointment, sulphur ointment, camphorated oil, crotamiton, choline esterase inhibitors, sulfacetamide, steroids, antibiotics, as well as antimycotic drugs, offers some improvement [9]. Oral administration of ivermectin along with topical application of cream permethrin is another quite suitable treatment for eyelash demodicosis [1,9]. Yet, in our outbreak report, patients responded well to tea tree oil treatment (TTO), as referred in other studies [2-5]. TTO scrub treatment seems effective for ocular Demodex elimination and improvement of ocular blepharitis symptoms [2,4]. In addition, TTO treatment is rather safe for clinical use, provided that proper patient education in eyelid scrub is available [2].

## Conclusion

In conclusion, Demodex spp may cause palpebra infections and palpebra skin lesions. Since our study has presented eyelash demodicosis to be quite spreadable in the community, every patient with chronic non-diagnosed blepharitis should be examined for *Demodex* spp. Tea tree oil treatment may be an efficient and safe choice against ocular demodicosis.

## References

- Holzchuh FG, Hida RY, Moscovici BK, Villa Albers MB, Santo RM, et al. (2011) Clinical treatment of ocular Demodex folliculorum by systemic ivermectin. Am J Ophthalmol 151: 1030-1034.
- Koo H, Kim TH, Kim KW, Wee SW, Chun YS, et al. (2012) Ocular surface discomfort and Demodex: effect of tea tree oil eyelid scrub in Demodex blepharitis. J Korean Med Sci 27: 1574-1579.
- Gao YY, Xu DL, Huang JJ, Wang R, Tseng SC (2012) Treatment of ocular itching associated with ocular demodicosis by 5% tea tree oil ointment. Cornea 31: 14-17.
- Gao YY, Di Pascuale MA, Elizondo A, Tseng SC (2007) Clinical treatment of ocular demodicosis by lid scrub with tea tree oil. Cornea 26: 136-143.
- Gao YY, Di Pascuale MA, Li W, Baradaran-Rafii A, Elizondo A, et al. (2005) In vitro and in vivo killing of ocular Demodex by tea tree oil. Br J Ophthalmol 89: 1468-1473.
- Textbook of Dermatology. Ed Rook A, Wilkinson DS, Ebling FJB, Champion RH, Burton JL. Fourth edition. Blackwell Scientific Publications.
- Wallace MM, Guffey DJ, Wilson BB (2016) Demodectic Frost of the Ear. JAMA Dermatol.
- Forton F, Germaux MA, Brasseur T, De Liever A, Laporte M, et al. (2005) Demodicosis and rosacea: epidemiology and significance in daily dermatologic practice. J Am Acad Dermatol 52: 74-87.
- Czepita D, Kuźna-Grygiel W, Czepita M, Grobelny A (2007) Demodex folliculorum and Demodex brevis as a cause of chronic marginal blepharitis. Ann Acad Med Stetin. 2007, 53: 63-67.