

Isolated Subcutaneous Metastasis of Myxoid Liposarcoma: A Case Report

Karima Mouden^{1*}, Amine Souadka², Mouna Khmou³, Afaf Semmar¹, Hanan El Kacemi¹, Tayeb Kebdani¹, Sanaa Majjaoui¹ and Nouredine Benjaafar¹

¹Department of Radiotherapy, National Institute of Oncology, University Mohammed V, Rabat, Morocco

²Department of Surgery, National Institute of Oncology, Rabat, Morocco

³Department of Pathology, National Institute of Oncology, Rabat, Morocco

Abstract

Background: Subcutaneous metastatic liposarcomas are rare. Differentiation between primary tumors and metastasis of a single liposarcoma represents the main difficulty in diagnosis. In this article, we describe the first report of Subcutaneous metastasis to the neck in the right level IB from liposarcoma originating in the thigh.

Case presentation: The present 19-year-old women presented to a complaint of a rapidly growing mass, of the posterior loge of the right thigh with poor definition of adjacent structures, of 9 months' duration measuring 188 × 97 mm.

Microscopic examination of the mass following excision revealed a myxoid liposarcoma. A wide surgical resection was performed, and margins were negative. At this time, the patient showed no metastatic disease and underwent a complementary treatment including irradiation of the right thigh at a dose of 50 Gy delivered in 25 fractions over 38 days. There weren't any local recurrence or metastases on her 12 months follow up until May 2015 when she presented with a mass in the neck (right level IB). An excisional biopsy was performed by an in June 2015 revealing a myxoid liposarcoma imposing a large re-excision of the tumor bed with 3cm free tumor margin.

Microscopic examination of the surgical specimen found clear margins without an involvement of the skin. Differentiation between primary tumors and metastasis of a single liposarcoma was very difficult. The results of the disease extension workup showed no sign of other metastases no local recurrence until now.

Conclusion: To our knowledge, no case of cutaneous metastatic myxoid liposarcoma has been reported until now.

Keywords: Subcutaneous; Metastasis; Myxoid liposarcoma

Introduction

Myxoid liposarcoma, the most common subtype of liposarcoma, occurs predominantly in the extremities of adults and has a tendency either to recur locally or to metastasize to unusual soft tissue locations [1,2].

A review of the literature revealed that cutaneous metastases of sarcoma represent 1% to 2.6% of all cutaneous metastases. Most of the writings were case reports that described skin involvement by various sarcomas, including leiomyosarcoma, Ewing sarcoma, osteosarcoma, and extraskeletal osteosarcoma [3-6].

To the best of our knowledge, This is the first case describing an isolated subcutaneous metastases to the neck of a primary myxoid liposarcoma of thigh occurring 2 years after the treatment of the initial tumor.

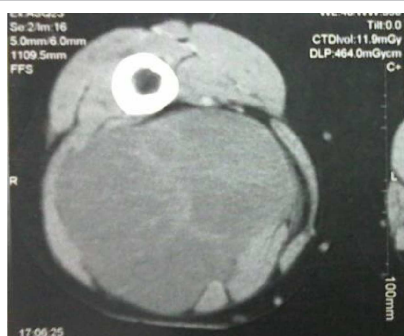

Figure 1a: CT: In homogenous masses of low density on CT in the posterior loge of the right thigh.

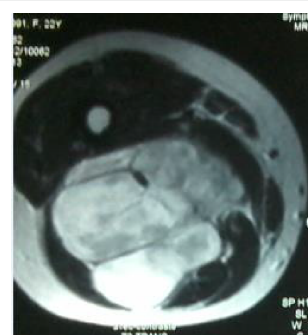

Figure 1b: T1-weighted MRI of thigh, axial view demonstrates well defined mass of hypersignal intensity.

Case Report

In September 2013, a 19-year-old women presented to a complaint of a rapidly growing mass, of the posterior loge of the

***Corresponding author:** Mouden Karima, Department of Radiotherapy, National Institute of Oncology, University Mohammed V, Rabat, Morocco, Tel : +22371990282 ; E-mail: moudenkarima@gmail.com

Received September 27, 2016; **Accepted** November 15, 2016; **Published** November 22, 2016

Citation: Mouden K, Souadka A, Khmou M, Semmar A, Kacemi HE, et al. (2016) Isolated Subcutaneous Metastasis of Myxoid Liposarcoma: A Case Report. J Clin Case Rep 6: 894. doi: [10.4172/2165-7920.1000894](https://doi.org/10.4172/2165-7920.1000894)

Copyright: © 2016 Mouden K, et al. This is an open-access article distributed under the terms of the Creative Commons Attribution License, which permits unrestricted use, distribution, and reproduction in any medium, provided the original author and source are credited.

right thigh with poor definition of adjacent structures, of 9 months' duration measuring 188 × 97 mm for her lower socioeconomic status (Figures 1a and 1b).

Microscopic examination of the mass following excision revealed a myxoid liposarcoma composed of abundant mucin deposition and a plexiform capillary network. The primary tumor was classified grade I according to the French federation of cancer centers sarcoma group (FNCLCC). A wide surgical resection was performed, and margins were negative. At this time, the patient showed no metastatic disease, and underwent a complementary treatment including irradiation of the right thigh at a dose of 50 Gy delivered in 25 fractions over 38 days. There weren't any local recurrence or metastases on her 12 months follow up until May 2015 when she presented with a mass in the neck (right level IB) (Figure 2). An excisional biopsy was performed by an in June 2015 revealing a myxoid liposarcoma imposing a large re-excision of the tumor bed with 3 cm free tumor margin (Figures 3-5).

Microscopic examination of the surgical specimen found clear margins without an involvement of the skin. Differentiation between primary tumors and metastasis of a single liposarcoma was very difficult. The results of the disease extension workup showed no sign of other metastases no local recurrence until now.

Discussion

Soft tissue sarcoma is a rare tumor that accounts for less than 1% of all malignant neoplasms in humans. Myxoid liposarcoma is the second most common subtype of liposarcoma and represents approximately 10% of all adult soft tissue sarcoma.

The three main morphologic subgroups are well-differentiated/dedifferentiated, myxoid/round cell, and pleomorphic liposarcomas [7-9].

Overall, about 25% of patients will develop distant metastatic

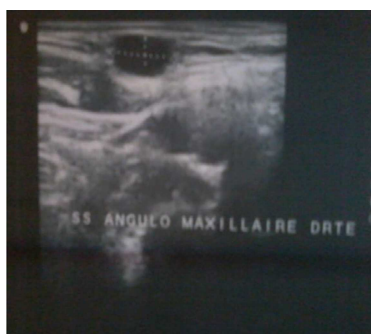

Figure 2: Cervical ultrasound demonstrates a mass in the neck (right level IB).

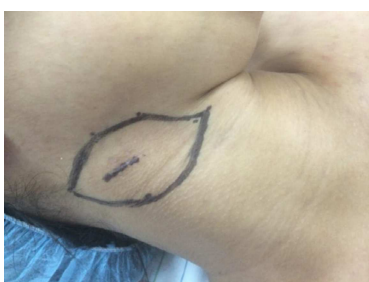


Figure 3: Showing location site of the incision and excisional margins.

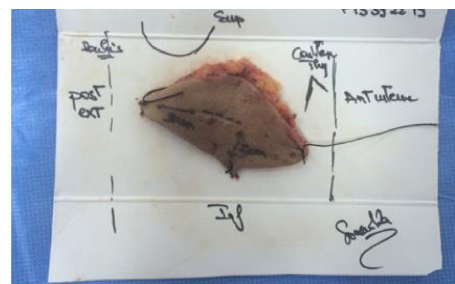


Figure 4: Showing oriented resection specimen.

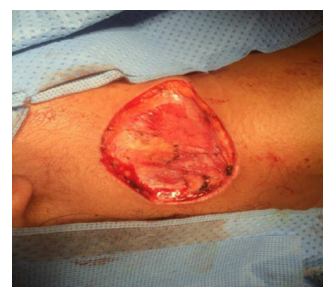

Figure 5: Showing preoperative view of the excisional site of the specimen.

disease after successful treatment of their primary tumor; the incidence increases till 40% to 50% of tumors that are >5 cm in size, deep to the fascia, and intermediate or high grade [10,11].

In 70% to 80% of cases, metastatic disease is to the lungs [12-15].

Rare sites of metastatic disease spread include the skin, soft tissues, bone, liver, heart and brain [12,16-23].

In a large study of American cancer society, leiomyosarcoma was the most common source of metastasis to the skin (43%), and the most common region of first skin metastasis was head and neck (51%) where the scalp predominated (38%) [24].

Other retrospective study (148 patients) found that metastases occur in approximately 30% of patients with dedifferentiated liposarcoma, with lung, liver and bone as the most frequent sites of metastases. The higher incidence of metastases may be due to referral and detection biases [25].

Surgical resection is the gold standard therapy for primary liposarcoma ensuring a wide excision with free margin. A complementary radiotherapy is associated with less recurrence [26]. Chemotherapy is an option only in the case of metastatic or unresectable disease [27].

Many authors agree that the myxoid and high-grade liposarcomas had tendency to produce metastasis during the first six months after removal of the primary tumor. In contrast, multicentric liposarcoma, developing from common locations (the thigh, retroperitoneum, arm or pleura) without metastasis to current areas (lung, liver, or bone), has a longer time interval between the development of lesions (5 to 10 years) [28].

Myxoid liposarcoma has a high prevalence of extrapulmonary metastases. The bones and soft tissues are the most common site of involvement, followed the lungs and liver. MRI is the most sensitive modality recommended in the detection of osseous and soft tissue metastases. FDG-PET shows no significant FDG uptake

for all metastases. Regarding myxoid liposarcoma, the disease-free interval, and the overall survival rate has been shown to be significantly better for patients with extrapulmonary metastases compared with those with pulmonary metastases. In fact, Cheng et al. reported in a series of 60 patients with liposarcoma, that patients with extrapulmonary metastasis have a longer disease-free interval from diagnostic to first metastasis than patients with pulmonary metastasis [29,30].

Due to the exceptional presentation of isolated cutaneous metastasis of liposarcoma to the neck, and according to the multidisciplinary meeting for cancer care's decision following the choice of the patient, only a wide surgery was performed. Till now the patient is under a regular medical surveillance that includes a review of a patient's medical history, a complete physical exam, MRI of the right thigh and neck ultrasound and remains disease free for eight months.

Conclusion

Subcutaneous metastases of sarcoma are rare. We have presented an extremely rare case of a solitary cutaneous metastatic in the neck arising from myxoid liposarcoma of the lower limbs.

Although treatment experience is limited owing to the rarity of this condition, our case report illustrates that, depending on a patient's overall condition. Complete curative resection may be considered as an optional treatment under the condition of well selected patient and close follow up.

References

- Goldblum JR, Weiss SW, Folpe AL (2014) Enzinger and Weiss's soft tissue tumors. (6th edn.) Philadelphia: Elsevier Inc; USA.
- Antonescu CR, Elahi A, Healey JH, Brennan MF, Lui MY, et al. (2000) Monoclonality of multifocal myxoid liposarcoma: Confirmation by analysis of TLS-CHOP or EWS-CHOP rearrangements. Clin Cancer Res 6: 2788-2793.
- Damron TA, Morganti C, Yang Y, Hojnowski L, Cherny R (2000) Metastasis of osteosarcoma to soft tissue. A case report. J Bone Joint Surg Am 82A: 1634-1638.
- Covello SP, Humphreys TR, Lee JB (2003) A case of extraskeletal osteosarcoma with metastasis to the skin. J Am Acad Dermatol 49: 124-127.
- Vandergriff T, Krathen RA, Orenko I (2007) Cutaneous metastasis of leiomyosarcoma. Dermatol Surg 33: 634-637.
- Biswas G, Khadwal A, Kulkarni P (2005) Ewing's sarcoma with cutaneous metastasis: A rare entity: report of 3 cases. Indian J Dermatol Venereol Leprol 71: 423-425.
- (2002) World Health Organization classification of tumours. In: Fletcher CD, Unni KK, Lyon MF (Eds.) In pathology and genetics of tumours of soft tissue and bone.
- Leona A, Doyle MD (2014) Sarcoma classification: An update based on the 2013 World Health Organization Classification of Tumors of Soft Tissue and Bone 120: 1763-1774.
- Conyers R, Young S, Thomas DM (2011) Liposarcoma: Molecular genetics and therapeutics. Sarcoma: 483154.
- Lindberg RD, Martin RG, Romsdahl MM, Barkley HT (1981) Conservative surgery and post-operative radiotherapy in 300 adults with soft-tissue sarcomas. Cancer 47: 2391.
- Weitz J, Antonescu CR, Brennan MF (2003) Localized extremity soft tissue sarcoma: improved knowledge with unchanged survival over time. J Clin Oncol; 21:2719.
- Potter DA, Glenn J, Kinsella T (1985) Patterns of recurrence in patients with high-grade soft-tissue sarcomas. J Clin Oncol 3: 353.
- Christie-Large M, James SL, Tiessen L (2008) Imaging strategy for detecting lung metastases at presentation in patients with soft tissue sarcomas. Eur J Cancer 44:1841.
- Billingsley KG, Lewis JJ, Leung DH (1999) Multifactorial analysis of the survival of patients with distant metastasis arising from primary extremity sarcoma. Cancer 85: 389.
- Rydholm A, Berg NO, Gullberg B (1984) Prognosis for soft-tissue sarcoma in the locomotor system. A retrospective population-based follow-up study of 237 patients. Acta Pathol Microbiol Immunol Scand A 92: 375.
- Xu J, Zheng Y, Wang L, Feng Q, Yu C (2014) Anesthetic management of the removal of a giant metastatic cardiac liposarcoma occupying right ventricle and pulmonary artery. J Cardiothorac Surg 9: 56.
- Mitomi M, Kimura K, Iguchi Y, Hayashida A, Nishimura H, et al. (2011) A case of stroke due to tumor emboli associated with metastatic cardiac liposarcoma. Intern Med 50: 1489-1491.
- Cuisset T, Fernandez C, Jolibert M, Unal C, Quilici J (2011) Acute coronary syndrome due to extrinsic compression of the left coronary system by metastatic liposarcoma successful treatment with percutaneous coronary intervention. J Am Coll Cardiol 58(19): 2014.
- Markovic ZZ, Mladenovic A, Banovic M, Ivanovic B (2012) Correlation of different imaging modalities in pre-surgical evaluation of pericardial metastasis of liposarcoma. Chin Med J 125: 3752-3754.
- Pino PG, Zampi G, Pergolini A, Pero G, Polizzi V, et al. (2013) Metastatic liposarcoma of the heart. Case series and brief literature review. Hertz 38: 938-942.
- Mottahedi B, Asadi M, Amini S, Alizadeh L (2013) Round cell liposarcoma metastatic to the heart. J Card Surg 28: 672-674.
- Vezeridis MP, Moore R, Karakousis CP (1983) Metastatic patterns in soft-tissue sarcomas. Arch Surg 118: 915.
- Ryzewicz M, McLoughlin HA, Freudenberger C (2008) Unusual metastases from extremity soft tissue sarcomas. Orthopedics 31: 439.
- Wang WL (2011) Sarcoma metastasis to the skin: A clinicopathologic study of 65 patients. Cancer VC 2011 American Cancer Society. Cancer 118(11):2900-2904.
- Tirumani SH, Tirumani H, Jagannathan JP (2015) Metastasis in de-differentiated liposarcoma: Predictors and outcome in 148 patients. Eur J Surg Oncol 41: 899-904.
- van Doorn RC, Gallee MP, Hart AA, Gortzak E, Rutgers EJ, et al. (1994) Resectable retroperitoneal soft tissue sarcomas. The effect of extent of resection and post-operative radiation therapy on local tumor control. Cancer 73: 637-642.
- Pápai Z, Bodoky G, Szántó J, Poller I, Rahóty P, et al. (2000) The efficacy of a combination of etoposide, ifosfamide, and cisplatin in the treatment of patients with soft tissue sarcoma. Cancer 89: 177-180.
- Conesa X, Seijas R, Ares o, Huguet P, Perez M (2011) Multicentric liposarcoma. Acta Orthop Belg 77: 9-14.
- Pearlstone DB, Pisters PW, Bold RJ, Feig BW, Hunt KK, et al. (1999) Patterns of recurrence in extremity liposarcoma: Implications for staging and follow-up. Cancer 85: 85-92.
- Cheng EY, Springfield DS, Mankin HJ (1995) Frequent incidence of extrapulmonary sites of initial metastasis in patients with liposarcoma. Cancer 75: 1120-1127.

Citation: Mouden K, Souadka A, Khmou M, Semmar A, Kacemi HE, et al. (2016) Isolated Subcutaneous Metastasis of Myxoid Liposarcoma: A Case Report. J Clin Case Rep 6: 894. doi: [10.4172/2165-7920.1000894](https://doi.org/10.4172/2165-7920.1000894)